

# Rehabilitation of the Knee After Medial Patellofemoral Ligament Reconstruction

Donald C. Fithian, MD<sup>a,b,c,\*</sup>, Christopher M. Powers, PhD, PT<sup>d,e</sup>,  
Najeeb Khan, MD<sup>b,c</sup>

## KEYWORDS

- Medial patellofemoral ligament • Reconstruction
- Rehabilitation • Exercise • Lower limb

Rehabilitation of the extensor mechanism after patellar stabilization surgery should be based on a sound understanding of lower limb mechanics, anatomy, mechanics of the injured or repaired extensor mechanism, and a careful evaluation of the patient. Abnormal anatomic features and control deficits can, and often do, affect function of the patellofemoral joint. Current evidence suggests that patellofemoral rehabilitation should address dynamic lower extremity function, such as abnormal lower extremity motions stemming from impairments proximally (ie, hip) or distally (ie, foot), because such motions can influence the dynamic quadriceps angle (Q-angle) (**Fig. 1**).<sup>1</sup> In addition, many patients with episodic patellar instability have preexisting anatomic deficiencies that may affect rehabilitation.<sup>2</sup> Joint surface injury and degenerative articular lesions also may call for variations to the rehabilitation protocol. The purpose of this article is to provide the reader with an understanding of the current state of lower limb rehabilitation for patients who have undergone medial patellofemoral ligament (MPFL) reconstruction.

---

Conflict of Interest: Dr Powers acknowledges a financial interest in the SERF Strap that was mentioned in this paper.

<sup>a</sup> Southern California Permanente Medical Group, San Diego, CA, USA

<sup>b</sup> Department of Orthopedic Surgery, Kaiser Permanente, 250 Travelodge Drive, El Cajon, CA 92020, USA

<sup>c</sup> San Diego Knee and Sports Medicine Fellowship, San Diego, CA, USA

<sup>d</sup> Musculoskeletal Biomechanics Research Laboratory, University of Southern California, Los Angeles, CA, USA

<sup>e</sup> Program in Biokinesiology, Division of Biokinesiology & Physical Therapy, University of Southern California, 1540 East Alcazar Street, CHP 155, Los Angeles, CA 90089-9006, USA

\* Corresponding author. Department of Orthopedic Surgery, Kaiser Permanente, 250 Travelodge Drive, El Cajon, CA 92020.

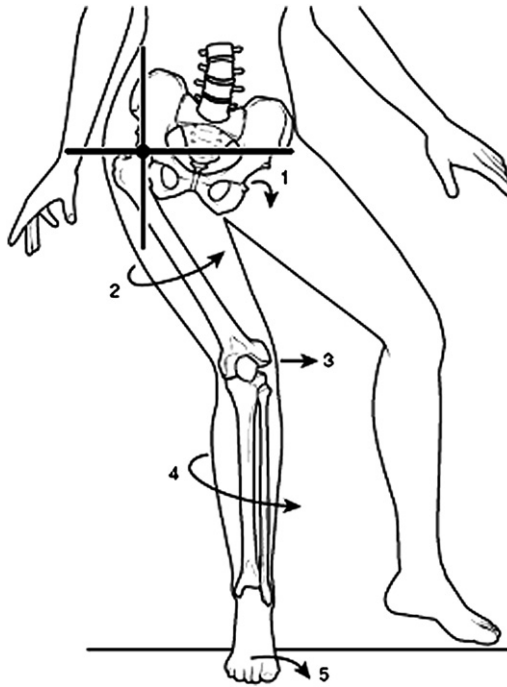
*E-mail address:* [donald.c.fithian@kp.org](mailto:donald.c.fithian@kp.org) (D.C. Fithian).

Clin Sports Med 29 (2010) 283–290

doi:10.1016/j.csm.2009.12.008

[sportsmed.theclinics.com](http://sportsmed.theclinics.com)

0278-5919/10/\$ – see front matter © 2010 Elsevier Inc. All rights reserved.



**Fig. 1.** A diagrammatic representation of the various potential contributions of limb malalignment and malrotation to increase Q-angle: (1) hip adduction, (2) femoral internal rotation, (3) genu valgum, (4) tibial external rotation, and (5) foot pronation. (From Powers CM. The influence of altered lower-extremity kinematics on patellofemoral joint dysfunction: a theoretical perspective. *J Orthop Sports Phys Ther* 2003;33(11):644; with permission.)

## PAIN AND SWELLING

MPFL reconstruction is a painful procedure. Severe postoperative pain can interfere with active muscle control. Pain can also impede progress with range of motion (ROM). Operating at or near the medial epicondyle of the knee often is associated with postoperative stiffness because of the higher degrees of motion of the injured soft tissues relative to the femur during knee flexion and extension. It is important to address this tendency aggressively in the early postoperative phase to avoid stiffness. Once the motion has been established, medial pain and knee stiffness caused by scarring at the femoral attachment of the graft are rare problems.

Swelling, either as free intra-articular fluid (effusion) or as soft tissue edema, also can interfere with joint motion. In addition, effusion inhibits quadriceps function<sup>3</sup> and may be harmful to intra-articular structures, such as articular cartilage.

Both pain and swelling can be addressed in various ways. Strict elevation of the limb and limited activity in the first 1 to 2 days postoperation allow the acute inflammatory phase to pass without further perturbation by overaggressive therapy. During that time, cold therapy may be helpful, whether in the form of ice packs or commercially available cold therapy units. The use of cold therapy to reduce local pain, inflammation, and swelling is a traditional mainstay of treatment after injury.

## ROM

Prolonged joint immobilization results in the loss of ground substance and dehydration of the extracellular matrix.<sup>4,5</sup> These changes reduce the distance between fibers within the matrix, causing friction and adhesion that reduce suppleness in periarticular ligaments and cartilage. In contrast, mobilization of an injured joint is associated with enhanced collagen synthesis and more optimal fiber realignment within the tissues, reversing the processes seen with immobilization.

It is not always possible to move joints immediately after surgery, but early motion is clearly desirable.<sup>6</sup> Experience has shown that immediate, controlled ROM is not detrimental to fixation or graft development in well-positioned and securely fixed ACL grafts. Furthermore, early motion seems to be beneficial to the limb as a whole by reducing pain, promoting healthy development of cartilage and periarticular tissues, and preventing scar formation and capsular contractions.<sup>7</sup> Therefore 1 goal of MPFL reconstruction is to use a competent graft, place it so that it will not be harmed by physiologic motion, and secure it well enough to withstand the loads associated with normal joint motion.

After MPFL reconstruction, loss of full passive extension is rarely seen. However, it can be difficult to regain full flexion. In addition, failure to achieve full active extension (residual extensor lag) has been reported at short and long-term follow-up.<sup>8</sup> The reasons for motion difficulties after MPFL reconstruction seem to be related to the dissection and MPFL graft location. Cyclops lesions, such as those that can physically block knee extension after ACL reconstruction, have not been reported after MPFL reconstruction. But capsular and/or infrapatellar fat pad contracture, quadriceps inhibition, and poorly positioned grafts can lead to the complications noted earlier.

An early goal of rehabilitation after MPFL reconstruction is to reestablish full knee extension. Unlike ACL reconstruction, return of passive knee extension does not guarantee full active extension. For that to occur, attention must focus on quadriceps strengthening (see later discussion for details). Pain and swelling can be mitigated with electrical stimulation, cold therapy, and compression wraps. Passive patellar glides should be instituted as soon as tolerated, to reestablish normal passive patellar mobility within the trochlear groove in all directions (superiorly, inferiorly, medially, and laterally). Many patients have considerable apprehension because of their prior experience with patellar hypermobility, and mobilization can improve confidence in their newly acquired patella stability.

Return of passive flexion can be difficult for several reasons. If the graft is not positioned properly it may tighten in flexion and tether the joint. Injury around the medial epicondyle, whether traumatic or surgical, is also associated with persistent joint stiffness if early attention is not given to full knee flexion in the rehabilitation program. The goal is to exceed 90° flexion within 6 weeks postoperatively. If that goal is achieved, then in the authors' experience limited knee flexion will not be a problem. On the other hand, delay in achieving greater than 90° of knee flexion may allow scar tissue proliferation and formation of adhesions around the graft and within the medial knee soft tissues. Manipulation may be required to regain full knee motion if flexion past 90° is not accomplished by week 6.

## QUADRICEPS STRENGTHENING

Surgery of the extensor mechanism is particularly prone to cause quadriceps inhibition and dysfunction, and every effort should be made to regain quadriceps control, strength, and endurance. If the reconstruction has been performed properly, then controlled quadriceps contractions pose no threat to the graft. Quadriceps setting

exercises should be started immediately after the surgery to keep the patellar tendon and infrapatellar fat pad stretched to their full length and to restore neuromuscular control. Resisted quadriceps and hamstring strengthening should be progressively used as the initial pain subsides.

A strong body of levels 1 and 2 studies indicates that electrical stimulation is helpful in reducing strength loss after knee ligament surgery. Classic studies on rehabilitation after ACL reconstruction have demonstrated the value of electrical stimulation compared with voluntary contractions alone for reducing postoperative abnormalities of gait and strength.<sup>9-11</sup> These earlier studies are supported by recent works, indicating that electrical stimulation combined with voluntary exercises is superior to voluntary exercises alone in restoring normal gait and strength.<sup>12</sup> A recent review of these studies recommended neuromuscular electrical stimulation in combination with volitional contraction. Previous investigators have emphasized early application of this approach, when muscle inhibition is most pronounced, to gain maximum effect.<sup>7</sup> Despite differences between MPFL and ACL reconstruction surgeries, there are enough similarities in postoperative neuromuscular deficiencies to suggest that strategies that are found to be successful after ACL reconstruction should be considered for those who have undergone MPFL reconstruction.

## **WEIGHT BEARING**

MPFL reconstruction, whether performed alone or in combination with osteotomy of the tibial tubercle, is not affected by axial loading of the joint. For this reason, there should be no *a priori* reason to limit weight bearing after surgery as long as axial rotation of the limb is not allowed. The limb should be splinted in a brace during weight-bearing activities for 4 to 6 weeks postoperatively or at least until limb control is sufficient to prevent falls and rotational stress on the knee. Early weight bearing should follow a gradual progression from full protection with a rigid brace locked at full extension to an unlocked brace with crutches. Gradual increase to full weight bearing should be permitted as quadriceps strength is restored.

Care should be taken during weight bearing to prevent dynamic knee valgus and hip internal rotation, which can cause abnormal loads on the healing graft. This is important because many patients with patellofemoral disorders have preexisting deficiencies in proximal limb control that can contribute to these motions.<sup>1,13,14</sup> When postoperative quadriceps weakness and neuromuscular inhibition is superimposed on poor proximal control, unprotected weight bearing can result in abnormal forces on the healing graft. A frequently cited study of graft healing in dogs suggested that 8 to 12 weeks are required for tendon-to-bone healing within tunnels to support graft tension without the risk of slippage.<sup>15</sup> For this reason, care is needed to avoid any rotational activity during the first 3 months postoperatively. Unprotected single-leg stance on the operated knee should be avoided until satisfactory proximal limb control has been achieved. The postoperative brace should be removed for resisted flexion and extension strengthening as well as other controlled rehabilitative exercises that do not cause knee valgus or axial rotational torque that would jeopardize the graft fixation.

Treatment to enhance proximal control can be started preoperatively and then immediately after surgery. Postoperatively, patients should perform non-weight bearing exercises targeting the hip abductors, external rotators, and extensors. When performing strengthening exercises for the gluteus medius, the patient must take care to minimize the contribution of the tensor fascia lata, because contraction of this muscle contributes to medial rotation of the lower extremity. Once the patient

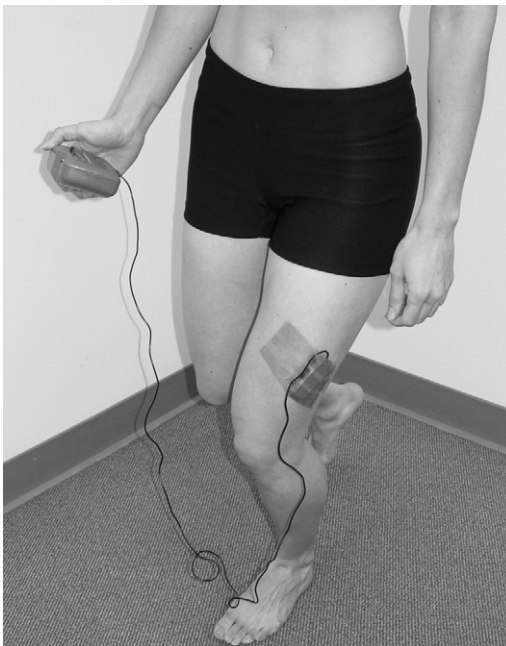
is able to isolate the proximal muscles of interest in non-weight bearing exercises, progression to weight-bearing activities can begin.

Facilitation of normal gait is an essential component of the overall treatment plan. This is particularly important for the returning athlete (especially runners), in whom even a slight gait deviation can be compounded by repetitive loading. The clinician should pay particular attention to the quadriceps avoidance gait pattern (walking with the knee extended or hyperextended). Because knee flexion during weight acceptance is critical for shock absorption,<sup>16</sup> this key function must be restored to prevent the deleterious effects of high-impact tibiofemoral joint loading.

The primary causes of quadriceps avoidance are pain, effusion, and quadriceps muscle weakness. As these impairments are addressed in other aspects of treatment, the clinician should keep in mind that resolution of symptoms may not readily translate into a normalized gait pattern. This is particularly evident in a patient with long-term pain and dysfunction. Movement patterns can be learned, and the patient may need to be reeducated with respect to key gait deficiencies. Electromyographic (EMG) biofeedback can be an effective tool for this purpose (**Fig. 2**).

### DYNAMIC LIMB STABILIZATION AND CONTROL

Functional training of the limb can begin in earnest 3 months after surgery. At this time, the patient should be introduced to the concept of neutral lower extremity alignment. This involves alignment of the lower extremity such that the anterior superior iliac spine and knee remain positioned over the second toe, with the hip positioned neutrally

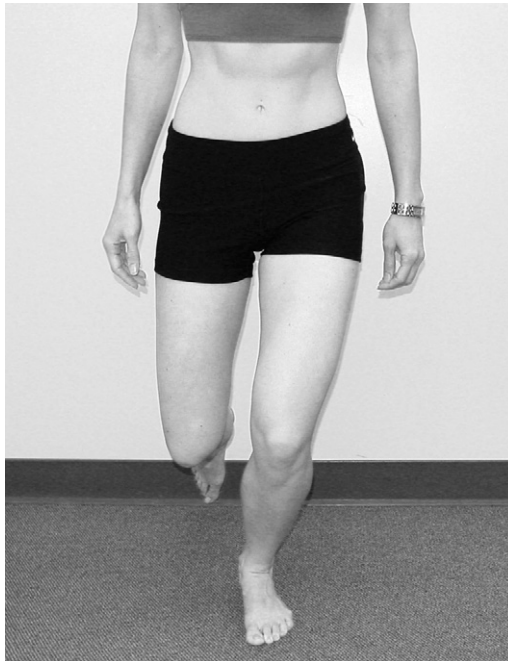

**Fig. 2.** EMG biofeedback can be used to facilitate quadriceps recruitment during functional tasks. (Reproduced from Powers CM, Souza RB, Fulkerson JP. Patellofemoral joint. In: Magee DJ, Zachazewski JE, Quillen WS, editors. Pathology and intervention in musculoskeletal rehabilitation. St. Louis (MO): Saunders Elsevier; 2008. p. 628; with permission.)

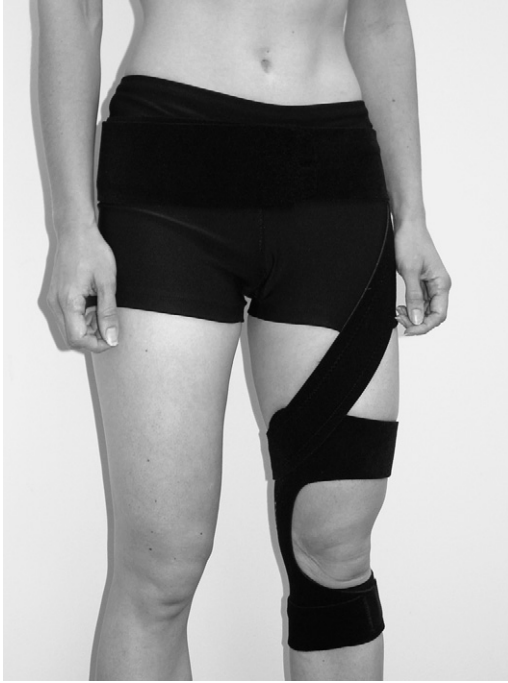(Fig. 3). Postural alignment and symmetric strengthening should be emphasized during all exercises (see Fig. 3).

If the patient has a difficult time maintaining proper lower extremity alignment during initial weight-bearing exercises, femoral strapping can be used to provide kinesthetic feedback and to augment muscular control and proprioception (Fig. 4). Also, taping or bracing of the patellofemoral joint may be done if pain is limiting the patient's ability to engage in a meaningful weight-bearing exercise program. Partial squats, which may have been started already in a controlled environment under supervision, can be advanced to incorporate a BOSU ball (BOSU Fitness LLC, San Diego, CA, USA) or a similar device to facilitate proximal control. Again many patients may exhibit abnormal movements or postures during training tasks. As such close supervision may be necessary to ensure proper execution. Once the patient understands the proper movement and goal of the task, continued performance in front of a mirror provides useful feedback.

As strength, control, and balance progress, single-leg activities may be initiated. This is the final step before returning to full unrestricted activity. Considering that most patients are conditioned by their preoperative apprehension caused by patellar instability and that some patients may not have performed single-leg squats on the operated leg for years before the operation, the patient may not progress to this stage before 5 to 6 months after the reconstruction. In any case, rehabilitation from this point onward requires careful assessment and progressive development of proximal lower limb control.



**Fig. 3.** Weight-bearing activities (such as the single-leg squat shown in the figure) should be done with particular attention to proper alignment of the pelvis, hip, knee, and ankle. (Reproduced from Powers CM, Souza RB, Fulkerson JP. Patellofemoral joint. In: Magee DJ, Zachazewski JE, Quillen WS, editors. Pathology and intervention in musculoskeletal rehabilitation. St. Louis (MO): Saunders Elsevier; 2008. p. 631; with permission.)



**Fig. 4.** Femoral strapping (Power Strap, Don Joy Orthopaedics Inc, Carlsbad, CA, USA) can be used to improve lower extremity control and kinematics during the rehabilitation program and functional activities. (*Reproduced from Powers CM, Souza RB, Fulkerson JP. Patellofemoral joint. In: Magee DJ, Zachazewski JE, Quillen WS, editors. Pathology and intervention in musculoskeletal rehabilitation. St. Louis (MO): Saunders Elsevier; 2008. p. 632; with permission.*)

## RETURN TO SPORT

Patients should be encouraged to return to their sport or activity gradually once they can achieve satisfactory single limb dynamic control. With competitive or recreational athletes who will be returning to full participation, plyometric training (ie, jump training) should be considered during this phase of the rehabilitation program. As patients, particularly athletes, return to sport activities, repetitive forces applied through the knee joint must be controlled adequately to allow continued healing of the injured or repaired tissues. During an extended time of recovery, such as following knee extensor mechanism surgery, quadriceps and hip muscle strength should be maintained (ie, maintenance program) through careful application of resistive exercises. Experience has shown that patients can expect to return to unrestricted activities by 6 months to 1 year postoperatively.

## REFERENCES

1. Powers CM. The influence of altered lower-extremity kinematics on patellofemoral joint dysfunction: a theoretical perspective. *J Orthop Sports Phys Ther* 2003;33: 639–46.
2. Fithian D, Neyret P, Servien E. Patellar instability: the Lyon experience. *Tech Knee Surg* 2007;6:112–23.

3. Palmieri-Smith RM, Kreinbrink J, Ashton-Miller JA, et al. Quadriceps inhibition induced by an experimental knee joint effusion affects knee joint mechanics during a single-legged drop landing. *Am J Sports Med* 2007;35:1269–75.
4. Vailas AC, Tipton CM, Matthes RD, et al. Physical activity and its influence on the repair process of medial collateral ligaments. *Connect Tissue Res* 1981;9:25–31.
5. Noyes FR. Functional properties of knee ligaments and alterations induced by immobilization: a correlative biomechanical and histological study in primates. *Clin Orthop Relat Res* 1977;123:210–42.
6. Haggmark T, Eriksson E. Cylinder or mobile cast brace after knee ligament surgery. A clinical analysis and morphologic and enzymatic studies of changes in the quadriceps muscle. *Am J Sports Med* 1979;7:48–56.
7. Manske R, DeCarlo M, Davies G, et al. Anterior cruciate ligament reconstruction: rehabilitation concepts. In: Kibler W, editor. *Orthopaedic knowledge update: sports medicine 4*. 4th edition. Rosemont (IL): American Academy of Orthopaedic Surgeons; 2009. p. 247–56.
8. Thauinat M, Erasmus PJ. Management of overtight medial patellofemoral ligament reconstruction. *Knee Surg Sports Traumatol Arthrosc* 2009;17:480–3.
9. Anderson AF, Lipscomb AB. Analysis of rehabilitation techniques after anterior cruciate reconstruction. *Am J Sports Med* 1989;17:154–60.
10. Wigerstad-Lossing I, Grimby G, Jonsson T, et al. Effects of electrical muscle stimulation combined with voluntary contractions after knee ligament surgery. *Med Sci Sports Exerc* 1988;20:93–8.
11. Snyder-Mackler L, Ladin Z, Schepesis AA, et al. Electrical stimulation of the thigh muscles after reconstruction of the anterior cruciate ligament. Effects of electrically elicited contraction of the quadriceps femoris and hamstring muscles on gait and on strength of the thigh muscles. *J Bone Joint Surg Am* 1991;73:1025–36.
12. Beynon BD, Johnson RJ, Abate JA, et al. Treatment of anterior cruciate ligament injuries, part 2. *Am J Sports Med* 2005;33:1751–67.
13. Souza RB, Powers CM. Predictors of hip internal rotation during running: an evaluation of hip strength and femoral structure in women with and without patellofemoral pain. *Am J Sports Med* 2009;37:579–87.
14. Souza RB, Powers CM. Differences in hip kinematics, muscle strength, and muscle activation between subjects with and without patellofemoral pain. *J Orthop Sports Phys Ther* 2009;39:12–9.
15. Rodeo SA, Arnoczky SP, Torzilli PA, et al. Tendon-healing in a bone tunnel. A biomechanical and histological study in the dog. *J Bone Joint Surg Am* 1993; 75:1795–803.
16. Perry J, Antonelli D, Ford W. Analysis of knee-joint forces during flexed-knee stance. *J Bone Joint Surg Am* 1975;57:961–7.